



<http://dx.doi.org/10.1016/j.jemermed.2017.04.032>

Clinical Review

EMERGENCY MEDICINE MYTHS: COMPUTED TOMOGRAPHY OF THE HEAD PRIOR TO LUMBAR PUNCTURE IN ADULTS WITH SUSPECTED BACTERIAL MENINGITIS – DUE DILIGENCE OR ANTIQUATED PRACTICE?

Michael D. April, MD, DPHIL, MSC,* Brit Long, MD,* and Alex Koyfman, MD†

*Department of Emergency Medicine, Brooke Army Medical Center, Fort Sam Houston, Texas and †Department of Emergency Medicine, The University of Texas Southwestern Medical Center, Dallas, Texas

Reprint Address: Brit Long, MD, Department of Emergency Medicine, Brooke Army Medical Center, 3841 Roger Brooke Dr., Fort Sam Houston, TX 78234

Abstract—Background: Various sources purport an association between lumbar puncture and brainstem herniation in patients with intracranial mass effect lesions. Several organizations and texts recommend head computed tomography (CT) prior to lumbar puncture in selected patients. **Objective:** To review the evidence regarding the utility of obtaining head CT prior to lumbar puncture in adults with suspected bacterial meningitis. **Discussion:** Observational studies report a risk of post-lumbar puncture brainstem herniation in the presence of intracranial mass effect (1.5%) that is significantly lower than that reported among all patients with bacterial meningitis (up to 13.3%). It is unclear from existing literature whether identifying patients with intracranial mass effect decreases herniation risk. Up to 80% of patients with bacterial meningitis experiencing herniation have no CT abnormalities, and approximately half of patients with intracranial mass effect not undergoing lumbar puncture herniate. Decision rules to selectively perform CT on only those individuals most likely to have intracranial mass effect lesions have not undergone validation. Despite recommendations for immediate antimicrobial therapy prior to imaging, data indicate an association between pre-lumbar puncture CT and antibiotic delays. Recent data demonstrate shortened door-to-antibiotic times and lower mortality from bacterial meningitis after implementation of new national

guidelines, which restricted generally accepted CT indications by removing impaired mental status as imaging criterion. **Conclusions:** Data supporting routine head CT prior to lumbar puncture are limited. Physicians should consider selective CT for those patients at risk for intracranial mass effect lesions based on decision rules or clinical gestalt. Patients undergoing head CT must receive immediate antibiotic therapy. Published by Elsevier Inc.

Keywords—lumbar puncture; brain computed tomography; bacterial meningitis; brainstem herniation; evidence-based medicine

INTRODUCTION

Bacterial meningitis is a deadly infection of the meninges. Contemporary estimates of mortality in large datasets from high-income countries range from 15–21% even in patients receiving antibiotic therapy (1,2). Time from presentation to antibiotic receipt is a critically important determinant of patient survival (3–5). Therefore, emergency physicians must actively consider this disease and aggressively administer antibiotics as quickly as possible among patients that they suspect have this deadly condition.

The reference standard diagnostic study for bacterial meningitis is analysis of cerebrospinal fluid (CSF) as

This review does not reflect the views or opinions of the U.S. government, Department of Defense, U.S. Army, U.S. Air Force, or SAUSHEC EM Residency Program.

RECEIVED: 17 January 2017; FINAL SUBMISSION RECEIVED: 5 April 2017;
 ACCEPTED: 25 April 2017

obtained by lumbar puncture (6). Completion of this procedure to obtain CSF for cultures early in the course of patient care is important to confirm the diagnosis and identify causative organisms to guide antimicrobial therapy (7). However, conventional wisdom holds that there is a potentially catastrophic consequence to the lumbar puncture procedure in certain patients. As stated in *Rosen's Emergency Medicine*, "In most patients with bacterial meningitis, [lumbar puncture (LP)] may be safely performed without antecedent neuroimaging studies. As this may not be the case in other brain diseases, in many circumstances it is advisable to obtain a CT scan of the head before LP is performed" (8). This claim reflects the concern that patients with brain edema or lesions causing intracranial mass effect may experience lumbar puncture-induced brainstem herniation (9).

A discord then exists between the imperative of rapid diagnosis and a rare but potentially fatal complication of the diagnostic procedure. Computed tomography (CT) provides physicians with a tool to identify those patients with brain lesions causing mass effect (10). The use of pre-lumbar puncture head imaging implies two important myths.

THE MYTHS

First, patients with mass effect lesions represent a group at significantly higher risk for brainstem herniation compared with the general population of patients with bacterial meningitis in whom lumbar puncture is uncontroversial. Second, providers may reliably prevent brainstem herniation in patients with intracranial lesions causing mass effect by forgoing lumbar puncture.

WHY IS THIS IMPORTANT?

Brainstem herniation is a devastating event frequently resulting in either death or profound neurologic morbidity (11). Emergency physicians might therefore consider pre-lumbar puncture CT in every patient with suspected bacterial meningitis to be conservative and safe practice. Yet this diagnostic strategy is not without consequence. Head imaging carries with it financial cost and patient exposure to radiation (12,13). More important is the potential for antibiotic delays associated with imaging. The Infectious Diseases Society of America (IDSA) guidelines and Emergency Medicine textbooks including *Rosen's* and *Tintinalli's* all recommend empiric antibiotic administration prior to imaging or lumbar puncture to avoid delays (Figure 1, an evaluation and management of meningitis algorithm) (8,14,15). Yet, despite this consensus, studies nevertheless consistently demonstrate that many patients undergoing head CT prior to lumbar puncture experienced antibiotic delays (4,16–18).

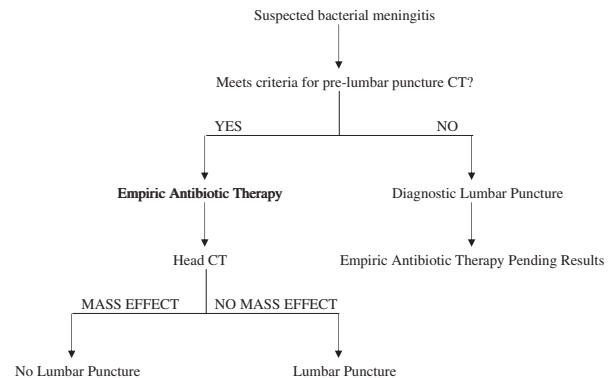


Figure 1. Diagnostic algorithm for adult patients with suspected bacterial meningitis. CT = computed tomography.

The standard practice to minimize these potential imaging consequences is to selectively perform pre-lumbar puncture CT on only those patients most likely to have intracranial lesions causing mass effect. Published decision rule studies, the IDSA guidelines, and the *Rosen's* and *Tintinalli's* texts all offer slightly different criteria for pre-lumbar puncture CT to rule out mass effect lesions (Table 1) (8,14–17). Regardless, this approach is controversial and has been subject to repeated criticism by advocates for fewer head CT scans for these patients (19). More definitive studies resolving this controversy are unlikely to be forthcoming given the rarity of bacterial meningitis and intracranial mass effect lesions and entrenched concerns about performing lumbar punctures in patients with intracranial mass effect lesions. Given the absence of such studies, this review seeks to provide emergency physicians an overview of the relevant existing primary literature so that they may better determine whether their adult patients with suspected bacterial meningitis should undergo head imaging prior to lumbar puncture.

LITERATURE REVIEW

We reviewed the peer-reviewed literature for studies reporting primary data related to the risk of post-lumbar puncture brainstem herniation. To this end we searched the PubMed database from inception through March 15, 2017. We constructed search terms to capture studies of clinical and imaging correlates with brainstem herniation risk and impact studies of alternative imaging strategies (Table 2). We reviewed the abstract of each item identified by the search strategy for possible inclusion into the review. We also reviewed the abstracts of studies cited in the bibliographies of included studies with titles potentially relevant to this review. We excluded nonprimary literature and case reports or series; studies reporting only diagnostic yield for lumbar puncture; studies reporting only nonherniation procedural complications; studies

Table 1. Criteria for Pre-Lumbar Puncture Computed Tomography of the Head in Patients with Suspected Bacterial Meningitis

| Criteria | Gopal et al. (16) | Hasbun et al. (17) | IDSA Guidelines (14) | Rosen's (8) | Tintinalli (15) |
|------------------------|-------------------|---|----------------------|-------------|--|
| Age | - | Age ≥ 60 y | - | - | Age > 60 y |
| Immune system | - | Immunocompromised | - | - | Immunocompromised |
| CNS disease | - | CNS disease | - | - | CNS disease |
| Seizure | - | Seizure within 1 week | - | - | New onset seizure |
| Trauma | - | - | - | - | History of seizures Evident head trauma |
| Malignancy | - | - | - | - | Any malignancy |
| Neurologic examination | - | Altered consciousness Inability to answer two questions Inability to follow two commands Gaze palsy Abnormal visual fields Facial palsy Arm drift Leg drift Abnormal language | - | - | Focal neurologic deficit Papilledema |

IDSA = Infectious Diseases Society of America; CNS = central nervous system.

Table 2. Search Strategy

| Sequence | Search Term* | Items |
|----------|-----------------------------|-----------|
| 1 | "Lumbar Puncture" [ti] | 1258 |
| 2 | "Intracranial hypertension" | 6890 |
| 3 | Papilledema | 4269 |
| 4 | Meningitis | 48,258 |
| 5 | "Brain Tumor" | 15,407 |
| 6 | #2 OR#3 OR#4 OR#5 | 73,293 |
| 7 | #1 AND#6 | 285 |
| 8 | Pediatrics | 361,576 |
| 9 | Child | 1,533,746 |
| 10 | Infant | 822,954 |
| 11 | #8 OR#9 OR#10 | 2,037,487 |
| 12 | #7 NOT#11 | 144 |

* Search restricted to English language studies only.

with pediatric patients; and studies of therapeutic lumbar puncture. We selected studies for final inclusion into the review by mutual agreement. In addition to primary literature, we included selected review articles to provide some historical context to the evolution of clinical practice related to screening for patients at high risk for post-lumbar puncture complications. We ultimately identified 12 articles reporting primary data relevant to the clinical question (Figure 2).

RESULTS

Historical Perspective

Contemporary authors generally attribute the first description of the needle lumbar puncture diagnostic procedure to Heinriche Quincke in 1891 (20). Studies published as early as 1896 reported periprocedural deaths in patients with presumed intracranial lesions while aptly noting the challenges of distinguishing causation vs. correlation (21).

On the basis of case series with autopsy data, in 1938 Geoffrey Jefferson proposed a mechanism by which lumbar puncture might precipitate brainstem herniation (22). He argued that in patients with intracranial lesions specifically causing mass effect, the CSF exerts a protective upward buoying effect on the brainstem. Should CSF removal occur in such a patient, he suggested the brainstem might herniate downward through the foramen magnum, resulting in devastating neurologic injury (22). This study marked an important milestone in the literature by positing a causative relationship between lumbar puncture and brainstem herniation.

Our literature review identified six observational studies subsequently published through the 1950s that examined outcomes among patients with presumed intracranial hypertension undergoing lumbar puncture (Table 3) (23–28). Although frequently cited as part of

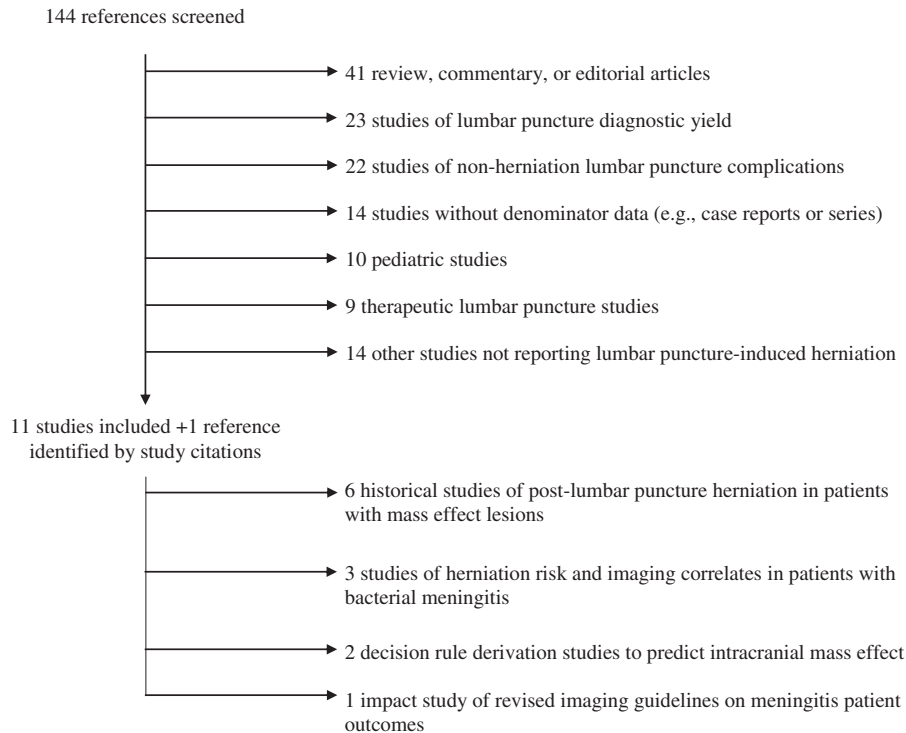


Figure 2. Literature review results.

discussions of the potential risks of lumbar puncture in patients with intracranial mass effect lesions, interpretation of these studies is difficult for several reasons (9). First, these studies predated the CT era. Consequently, authors relied upon a combination of clinical suspicion for brain tumor, subsequent histological verification of brain tumor by CSF analysis or autopsy, or papilledema in selecting their patients for these studies (23–28). These alternative inclusion criteria may yield dramatically different patient populations in terms of intracranial findings. Presuming intracranial mass effect lesions in patients with papilledema alone is particularly problematic as papilledema may occur in conditions without any mass effect lesions (e.g., idiopathic intracranial hypertension – a disease for which lumbar puncture is actually therapeutic) (29).

Regardless, the risk of post-lumbar puncture neurologic deterioration attributed to brainstem herniation reported by these studies was variable, ranging from 0–6.2% (25,27,28). Taken in aggregate, these data suggest an overall herniation risk of 1.5%. A single publication reported a case of rapid neurologic decline within 5 min of lumbar puncture (28). All other cases experienced decline hours after the procedure (range 3–24 h), which casts some doubt on a causative relationship between the lumbar puncture and patient outcome (23,24,26,28). Moreover, at least one study further reported experience with patients with presumed intracranial mass effect lesions who experienced neurologic deterioration despite forgoing lumbar puncture (24).

It is difficult to extrapolate from these data the risk of lumbar puncture-induced brainstem herniation

Table 3. Risk of Post-Lumbar Puncture Neurologic Deterioration in Patients with Presumed Intracranial Mass Effect Lesions

| Author | Year | Cases | Inclusion Criteria | Post-LP Complications (%) |
|----------------------|------|-------|--|---------------------------|
| Masson (23) | 1927 | 200 | Presumed brain tumor | 1 (0.5%) |
| Schaller (24) | 1933 | 103 | Papilledema or presumed brain tumor | 4 (3.9%) |
| Hepburn (25) | 1938 | 25 | Papilledema | 0 (0%) |
| Lubic & Marotta (26) | 1954 | 401 | Verified tumor | 1 (0.2%) |
| Sencer (27) | 1956 | 87 | Papilledema | 0 (0%) |
| Korein et al. (28) | 1959 | 129 | Papilledema or opening CSF pressure > 25 cm H ₂ O | 8 (6.2%) |
| Total | | 945 | | 14 (1.5%) |

LP = lumbar puncture; CSF = cerebrospinal fluid.

attributable to intracranial mass effect lesions as diagnosed in the contemporary era (i.e., head CT), given that these studies predated the availability of advanced head imaging techniques. By the time CT became widely available, the medical community had largely granted the premise that patients with these intracranial lesions were at higher risk for procedure-related complications. This premise precluded more definitive study. Indeed, data regarding the risk of lumbar-puncture-induced brainstem herniation in the presence of intracranial mass effect lesions as confirmed by head imaging is largely limited to case series (10).

Herniation Risk and Imaging Correlates in Patients with Bacterial Meningitis

The literature reports a significant incidence of brainstem herniation among patients with bacterial meningitis, which may exceed that among patients with intracranial mass effect lesions undergoing lumbar puncture. Our literature review identified three studies with denominator data reporting the risk of brainstem herniation in patients with bacterial meningitis. First, a pre-CT-era study from Massachusetts General Hospital spanning 1956–1962 reported autopsy-confirmed brainstem herniation in 9 (5.1%) of 175 patients undergoing lumbar puncture (30). Whereas 4 of these patients had widespread cerebral edema, the authors report no anatomic abnormalities for the other patients.

Two additional studies from the CT era in Germany report cases of patients experiencing post-lumbar puncture herniation despite an absence of intracranial radiographic mass effect lesions. First, a prospective German cohort of 86 patients with bacterial meningitis undergoing lumbar puncture reported periprocedural herniation in 7 patients (8.1%), of whom 3 (42.9%) had no CT evidence of brain edema causing mass effect (31). Second, an analysis of 75 patients with proven pneumococcal meningitis reported 10 (13.3%) patients experiencing brainstem herniation. Eight (80%) of these patients had no associated head CT abnormalities (32). Based on these results, it is unclear whether head imaging can reliably identify those patients with bacterial meningitis at greatest risk for post-lumbar puncture herniation.

Another vexing question is whether reliable identification of these patients could prevent brainstem herniation through the deferral of lumbar puncture. Although it seems intuitive that this should be possible, data from several studies further undermine the presumed causal relationship between this procedure and outcome. One patient in the Massachusetts General Hospital case series experienced brainstem herniation preceding lumbar puncture (30). In a Yale-based head imaging decision rule-derivation study (discussed further below), 4 patients

had head imaging results suggestive of mass effect lesions; though none of these patients underwent lumbar puncture, 2 (50%) nevertheless herniated (17).

On the basis of these data, patients with bacterial meningitis seem to be at particularly high risk for brainstem herniation. However, it remains questionable whether head imaging can identify within this population a subgroup in whom providers may attenuate this risk by forgoing lumbar puncture. Of course, bacterial meningitis is rare (diagnosed in 1.7% of ED patients undergoing lumbar puncture in one study) and becoming more so given the advent of the pneumococcal conjugate vaccine (17,33). As such, the impact of diagnostic approach to patients with suspected bacterial meningitis will be driven in greater part by outcomes among the majority of patients without meningitis. Nevertheless, we believe the data from patients with bacterial meningitis is instructive in highlighting the limited evidence base supporting the notion that providers may prevent brainstem herniation in patients undergoing lumbar puncture by screening out individuals with particular head CT abnormalities.

Decision Rule Studies

Despite the limitations in data linking lumbar puncture to brainstem herniation, at the turn of the millennium many authors and professional societies continued to advocate for pre-lumbar puncture CT imaging to rule out mass effect lesions. The presumed benefit of this approach is to prevent brainstem herniation by forgoing lumbar puncture in patients with intracranial mass effect lesions and to identify any alternative neurologic abnormalities (10,34,35). Our literature review identified two decision-rule derivation studies seeking to balance the competing priorities of limiting radiation exposure and antibiotic delays associated with imaging vs. identifying patients with intracranial lesions potentially placing them at higher risk for post-lumbar puncture herniation. The aim of these decision rules is to selectively image only those patients with clinical features associated with head CT abnormalities.

The first study, by Gopal et al., examined consecutive ED patients requiring lumbar puncture while in the ED for any indication (e.g., diagnostic work-up for subarachnoid hemorrhage or bacterial meningitis) (16). Providers completed data collection forms regarding 10 variables related to patient presentation, medical history, and examination characteristics. They captured 111 of 113 consecutive patients, all of whom underwent preceding head CT. They identified three significant predictors of any head CT abnormality: altered mental status, focal neurologic examination abnormality, and papilledema (Table 1). The authors note their belief that no single one of these

characteristics has sufficient accuracy to adequately predict CT abnormalities, but in aggregate, the three screening items may serve as an effective screening tool. Patients with none of the three characteristics have a negative likelihood ratio (LR⁻) for any CT abnormality (not mass effect lesions specifically – see discussion below) of 0.0, 95% confidence interval (CI) 0–0.6. Presence of one or more characteristics yielded a positive likelihood ratio (LR⁺) of 1.6, 95% CI 1.2–1.9. Of note, the investigators also asked physicians to predict based on clinical level of suspicion whether the patient would have an intracranial lesion contraindicating lumbar puncture, which demonstrated similar diagnostic accuracy for any CT abnormality: LR⁺ 18.8, 95% CI 4.8–43, and LR⁻ 0.0, 95% CI 0.0–0.7 (16). These results suggest that clinical gestalt may outperform this decision rule in determining which patients most need head imaging.

The second study, by Hasbun et al., is arguably more relevant to our clinical question, as their focus was solely upon ED patients undergoing evaluation for suspected bacterial meningitis (17). This study prospectively enrolled 301 patients regardless of whether they ultimately underwent head imaging or lumbar puncture. They collected data on a range of variables including demographics, comorbidities, and physical examination. Of these patients, 235 (78.1%) underwent head CT, and it is from this group that the authors derived their decision rule. They determined significant associations between any head CT abnormality (once again, not specific to mass effect lesions) and the following characteristics: age > 59 years, immunocompromised state, history of central nervous system disease, seizures in the past week, and various neurologic examination abnormalities (Table 1). Taken together to serve as a decision rule, the absence of any of these criteria results in LR⁻ 0.1. The presence of one or more criteria yields LR⁺ 2.0 (17).

A decision rule-based diagnostic approach to patients with suspected bacterial meningitis has found widespread support in the literature (8,15,35,36). The IDSA guidelines for the management of bacterial meningitis specifically advocate that clinicians utilize criteria largely based upon the decision rule derived by Hasbun et al. in determining which patients should undergo head CT prior to lumbar puncture (14,17). Yet the Hasbun and Gopal studies alike have important limitations, even if granting the questionable premise that patients with intracranial mass effect lesions should not undergo lumbar puncture (16,17).

First, the Hasbun et al. study calculated test characteristics including only those patients who underwent head CT (17). In fact, providers will apply this decision rule to the broader population of all patients with suspected bacterial meningitis, including those not undergoing any imaging. Although it is likely that these patients

who did not undergo CT appeared clinically well and may well not have met any decision rule criteria (so resulting in higher decision rule accuracy), it is impossible to know based on the data reported.

Second, the Hasbun and Gopal studies are both derivation studies (16,17). To our knowledge, neither decision rule has undergone validation. Prior to widespread use and acceptance, these rules should have undergone validation in settings external to the sites of derivation. Moreover, such validation studies ideally would have relied upon measurements of the efficacy by clinicians rather than investigators (37). The literature discusses expectations of rigorous external clinical validation studies extensively for other disease processes in emergency medicine (e.g., subarachnoid hemorrhage) (38). Yet this major limitation of the bacterial meningitis imaging decision rules has gone largely unchallenged.

Data exploring the impact of decision rule use on definitive patient outcomes are limited. Studies directly comparing decision rule-based imaging against strategies of either routine CT or lumbar puncture without CT are unlikely to be forthcoming. Such studies would be prohibitively expensive given the infrequency of occurrence of many of the outcomes of interest. Yet the existing data from both Gopal et al. and Hasbun et al. suggest that a serious potential consequence of pre-lumbar puncture CT is prolonged time to receipt of antibiotics (16,17).

Gopal et al. reported that 2 of 3 patients with positive CSF cultures did not receive antibiotics prior to lumbar puncture while awaiting head CT (mean delay 2.8 h) (16). Similarly, Hasbun et al. reported a trend toward prolonged time from ED arrival to antibiotic receipt for those patients undergoing head CT vs. no head CT (mean 3.8 vs. 2.9 h) (17). Thus, despite consistent recommendations across textbooks and guidelines for immediate antibiotic administration prior to CT, an association nevertheless persists between pre-lumbar puncture imaging and prolonged door-to-antibiotic time. These differences are significant given data suggesting that each hour of delay in antibiotic administration may result in a 30% rise in mortality (5).

Impact Study

We identified a single study with data supporting the notion that these decisions regarding diagnostic pathways have a material impact on patient outcomes at the population level. In 2009, Swedish guidelines were revised by removing “impaired mental status” as a decision rule criterion precluding lumbar puncture. Subsequently, official statistics demonstrated a reduction in door-to-antibiotic times and a concomitant reduction in mortality from 11.7% to 6.9% (19,39). Although further data and replication of these results are necessary, they highlight

the potential survival benefits of more restrictive use of head CT among patients with suspected bacterial meningitis.

BOTTOM LINE AND CONCLUSIONS

In patients with intracranial lesions causing mass effect, there is a theoretical concern that the CSF exerts a protective buoying effect and that its removal will precipitate brainstem herniation. However, observational data indicate that the risk of brainstem herniation attributable to intracranial mass effect lesions is low (~1.5%). Indeed, the herniation risk seems far greater among patients with bacterial meningitis (up to 13.3%), the very disease process requiring lumbar puncture for diagnosis and not considered to be a contraindication to this procedure.

It is unclear whether CT is an effective screening tool, as studies report that up to 80% of patients with bacterial meningitis experiencing brainstem herniation have no evidence of mass effect on head imaging. The clinical utility of identifying those patients with intracranial mass effect is similarly questionable, as the existing literature suggests that up to half of these patients may herniate despite providers forgoing lumbar puncture. Finally, whereas the Hasbun et al. decision aid endorsed by most emergency medicine textbooks and the IDSA guidelines helps to rule out intracranial mass effect without imaging (LR=0.1), it has never undergone any validation (17).

The central issue with CT prior to lumbar puncture relates to prolonged door-to-antibiotic time. Emergency medicine texts and the IDSA guidelines alike recommend immediate antibiotic therapy prior to lumbar puncture. However, multiple observational studies nevertheless report delays in antibiotic administration among patients undergoing CT prior to lumbar puncture. The reasons for and mechanisms to mitigate these delays are an important area for future research. However, data from Sweden indicate that one such effective mechanism may be alterations to imaging indications, as they report shortened door-to-antibiotic times and improved survival after removal of “impaired mental status” from the list of criteria mandating pre-lumbar puncture imaging. Pending the results of additional studies refining and validating changes to these criteria, emergency physicians should continue to focus on ensuring immediate antibiotic administration in those patients with suspected bacterial meningitis in whom they plan to obtain CT imaging.

REFERENCES

1. Thigpen MC, Whitney CG, Messonnier NE, et al. Bacterial meningitis in the United States 1998–2007. *N Engl J Med* 2011;364:2016–25.

2. van de Beek D, de Gans J, Spanjaard L, Weisfelt M, Reitsma JB, Vermeulen M. Clinical features and prognostic factors in adults with bacterial meningitis. *N Engl J Med* 2004;351:1849–59.
3. Aronin SI, Peduzzi P, Quagliarello VJ. Community-acquired bacterial meningitis: risk stratification for adverse clinical outcome and effect of antibiotic timing. *Ann Intern Med* 1998;129:862–9.
4. Proulx N, Frechette D, Toye B, Chan J, Kravcik S. Delays in the administration of antibiotics are associated with mortality from adult acute bacterial meningitis. *QJM* 2005;98:291–8.
5. Koster-Rasmussen R, Korshin A, Meyer CN. Antibiotic treatment delay and outcome in acute bacterial meningitis. *J Infect* 2008;57:449–54.
6. McGill F, Heyderman RS, Panagiotou S, Tunkel AR, Solomon T. Acute bacterial meningitis in adults. *Lancet* 2016;388:3036–47.
7. Michael B, Menezes BF, Cunniffe J, et al. Effect of delayed lumbar punctures on the diagnosis of acute bacterial meningitis in adults. *Emerg Med J* 2010;27:433–8.
8. Meurer WJ. Central nervous system infections. In: Marx J, Hockberger R, Walls R, eds. *Rosen’s emergency medicine*. 8th edn. Philadelphia, PA: Saunders; 2014:1447–59.
9. van Crevel H, Hijdra A, de Gans J. Lumbar puncture and the risk of herniation: when should we first perform CT? *J Neurol* 2002;249:129–37.
10. Gower DJ, Baker AL, Bell WO, Ball MR. Contraindications to lumbar puncture as defined by computed cranial tomography. *J Neurol Neurosurg Psychiatry* 1987;50:1071–4.
11. Duffy GP. Lumbar puncture in the presence of raised intracranial pressure. *Br Med J* 1969;1:407–9.
12. Centers for Medicare and Medicaid Services. Physician fee schedule. Baltimore; 2015. Available at: <http://www.cms.gov/>. Accessed October 4, 2016.
13. Brenner DJ, Hall EJ. Computed tomography—an increasing source of radiation exposure. *N Engl J Med* 2007;357:2277–84.
14. Tunkel AR, Hartman BJ, Kaplan SL, et al. Practice guidelines for the management of bacterial meningitis. *Clin Infect Dis* 2004;39:1267–84.
15. Tanski ME, Ma OJ. Central nervous system and spinal infections. In: Tintinalli JE, Stapczynski JS, Ma OJ, et al., eds. *Tintinalli’s emergency medicine*. New York: McGraw-Hill Education; 2016:1192–8.
16. Gopal AK, Whitehouse JD, Simel DL, Corey GR. Cranial computed tomography before lumbar puncture: a prospective clinical evaluation. *Arch Intern Med* 1999;159:2681–5.
17. Hasbun R, Abrahams J, Jekel J, Quagliarello VJ. Computed tomography of the head before lumbar puncture in adults with suspected meningitis. *N Engl J Med* 2001;345:1727–33.
18. Auburtin M, Wolff M, Charpentier J, et al. Detrimental role of delayed antibiotic administration and penicillin-nonsusceptible strains in adult intensive care unit patients with pneumococcal meningitis: the PNEUMOREA prospective multicenter study. *Crit Care Med* 2006;34:2758–65.
19. Glimaker M, Lindquist L, Sjolín J. Working Party of the Swedish Infectious Disease Society for Bacterial CNSI. Lumbar puncture in adult bacterial meningitis: time to reconsider guidelines? *BMJ* 2013;346:f361.
20. Frederiks JA, Koehler PJ. The first lumbar puncture. *J Hist Neurosci* 1997;6:147–53.
21. Furbringer P. Plotzliche Todesfalle nach Lumbalpunktion. *Centralblatt fur Innere Medizin* 1896;17:1–8. [in German].
22. Jefferson G. The tentorial pressure cone. *Arch Neurol Psych* 1938;40:857–76.
23. Masson CB. The dangers of diagnostic lumbar puncture in increased intracranial pressure due to brain tumor, with a review of 200 cases in which lumbar puncture was done. *Res Nerv Ment Dis Proc* 1927;8:422.
24. Schaller WF. The propriety of diagnostic lumbar puncture in intracranial hypertension. *J Neurol Psychopathol* 1933;14:116–23.
25. Hepburn HH. The risk of spinal puncture. *Can Med Assoc J* 1938;39:449–50.
26. Lubic LG, Marotta JT. Brain tumor and lumbar puncture. *AMA Arch Neurol Psychiatry* 1954;72:568–72.

27. Sencer W. The lumbar puncture in the presence of papilledema. *J Mt Sinai Hosp N Y* 1956;23:808–15.
28. Korein J, Cravioto H, Leicach M. Reevaluation of lumbar puncture; a study of 129 patients with papilledema or intracranial hypertension. *Neurology* 1959;9:290–7.
29. van Crevel H. Papilloedema, CSF pressure, and CSF flow in cerebral tumours. *J Neurol Neurosurg Psychiatry* 1979;42:493–500.
30. Dodge PR, Swartz MN. Bacterial meningitis—a review of selected aspects. II. Special neurologic problems, postmeningitic complications and clinicopathological correlations. *N Engl J Med* 1965;272:954–60.
31. Pfister HW, Feiden W, Einhaupl KM. Spectrum of complications during bacterial meningitis in adults. Results of a prospective clinical study. *Arch Neurol* 1993;50:575–81.
32. Kastenbauer S, Winkler F, Pfister HW. Cranial CT before lumbar puncture in suspected meningitis. *N Engl J Med* 2002;346:1248–51. author reply 1248–51.
33. Hsu HE, Shutt KA, Moore MR, et al. Effect of pneumococcal conjugate vaccine on pneumococcal meningitis. *N Engl J Med* 2009;360:244–56.
34. American Academy of Neurology. Practice parameters: lumbar puncture (summary statement). Report of the Quality Standards Subcommittee of the American Academy of Neurology. *Neurology* 1993;43:625–7.
35. Zaidat OO, Suarez JI. Computed tomography for predicting complications of lumbar puncture. *JAMA* 2000;283:1004.
36. Joffe AR. Lumbar puncture and brain herniation in acute bacterial meningitis: a review. *J Intensive Care Med* 2007;22:194–207.
37. Stiell IG, Wells GA. Methodologic standards for the development of clinical decision rules in emergency medicine. *Ann Emerg Med* 1999;33:437–47.
38. Perry JJ, Stiell IG, Sivilotti ML, et al. Sensitivity of computed tomography performed within six hours of onset of headache for diagnosis of subarachnoid haemorrhage: prospective cohort study. *BMJ* 2011;343:d4277.
39. Glimaker M, Johansson B, Grindborg O, Bottai M, Lindquist L, Sjolín J. Adult bacterial meningitis: earlier treatment and improved outcome following guideline revision promoting prompt lumbar puncture. *Clin Infect Dis* 2015;60:1162–9.

ARTICLE SUMMARY

1. Why is this topic important?

A theoretical concern exists that lumbar puncture performed in patients with intracranial mass effect lesions can result in brainstem herniation. This procedure is common in the emergency department setting, and several authors and guidelines recommend that some patients undergo preprocedure brain computed tomography (CT) to identify those patients with intracranial abnormalities who should not undergo lumbar puncture.

2. What does this review attempt to show?

This review evaluates the literature supporting head CT prior to lumbar puncture in adults with suspected bacterial meningitis.

3. What are the key findings?

Historic data suggest a small risk ($\sim 1.5\%$) of post-lumbar puncture herniation in patients with intracranial mass effect lesions. The literature suggests that many of these patients will experience herniation even if physicians forgo lumbar puncture. Decision rules recommended by many to minimize to selectively perform CT on only those patients most likely to benefit from forgoing lumbar puncture do not detect mass effect lesions specifically but rather any head CT abnormality. Meanwhile, despite guideline and textbook recommendations to administer immediate antibiotics prior to CT, multiple observational studies report an association between pre-lumbar puncture imaging and prolonged door-to-antibiotic time.

4. How is patient care impacted?

Physicians should order pre-lumbar puncture head CT imaging judiciously based on decision rules or clinical gestalt to identify those patients at risk for intracranial mass effect lesions. Patients undergoing head CT should receive immediate antimicrobial therapy in accordance with guidelines.