

Prospective Validation of a Clinical Score for Males

Presenting with an Acute Scrotum

Lillian C. Frohlich, MPH,^{1,2} Niloufar Paydar-Darian, MD,²

Bartley G. Cilento, Jr. MD, MPH,³ Lois K. Lee, MD, MPH²

¹Bioverativ, Waltham, MA

²Division of Emergency Medicine, Boston Children's Hospital, Boston, MA

³Department of Urology, Boston Children's Hospital, Boston, MA

Corresponding author:

Lois K. Lee, MD, MPH
Division of Emergency Medicine
Boston Children's Hospital
300 Longwood Ave.
Boston, MA 02115
Phone: 617-355-5089
Fax: 617-730-0335
Email: lois.lee@childrens.harvard.edu

LCF reports no conflict of interest.
NPD reports no conflict of interest.
BGC reports no conflict of interest.
LKL reports no conflict of interest.
No external funding was received for this research.

LKL conceived the study and designed the trial. LKL and BC supervised the conduct of the trial and the data collection. LCF undertook recruitment of the patients and managed the data, including quality control. LCF and LKL analyzed the data. LCF, NPD, BC, and LKL interpreted the data. LCF and LKL drafted the manuscript, and all authors critically reviewed the manuscript. LKL takes responsibility for the paper as a whole.

This article has been accepted for publication and undergone full peer review but has not been through the copyediting, typesetting, pagination and proofreading process, which may lead to differences between this version and the Version of Record. Please cite this article as doi: 10.1111/acem.13295-17-412

This article is protected by copyright. All rights reserved.

ABSTRACT

Objective: To validate the Testicular Workup for Ischemia and Suspected Torsion (TWIST) score among pediatric emergency medicine providers for the evaluation of pediatric males presenting with testicular pain and swelling (acute scrotum).

Methods: We conducted a prospective cohort study of males 3 months to 18 years old presenting with an acute scrotum. History and physical examination findings, including components of the TWIST score (hard testicle, absent cremasteric reflex, nausea/vomiting, and high riding testicle) as well as diagnostic results (ultrasound, urine, sexually transmitted infection (STI) testing) were recorded. Testicular torsion was confirmed by surgical exploration. Frequencies of patient characteristics, TWIST components, and tests were calculated. We performed the kappa statistic for inter-rater reliability and calculated the test characteristics and receiver operator curves for the TWIST score (range 0-7).

Results: During the study period 258 males were enrolled in the study; 19 (7.4%) had testicular torsion. The mean age was 9.8 years (\pm 0.3 years). The high-risk TWIST score of 7 had 100% specificity (95% confidence interval (CI) 98%, 100%) with 100% positive predictive value (95% CI 40%, 100%) for testicular torsion. The area under the curve was 0.82. The kappa statistic for the overall TWIST score was fair at 0.39.

Conclusions: In this prospective validation of the TWIST score among pediatric emergency providers, the high-risk score demonstrated strong test characteristics for testicular torsion. The TWIST score could be used as part of a standardized approach for evaluation of the pediatric acute scrotum to provide more efficient and effective care.

Key words

Acute scrotum
Testicular
Torsion

Abbreviations

AUC: area under the curve
CI: confidence interval
DUS: Doppler Ultrasonography
ED: emergency department
EMT: emergency medical technicians
Hpf: high power field
LR: likelihood ratio
NAAT: nucleic acid amplification test
NPV: negative predictive value
PPV: positive predictive value
OR: odds ratio
ROC: receiver operator characteristic
STI: sexually transmitted infection
TWIST: Testicular Workup for Ischemia and Torsion
UA: urinalysis
UTI: urinary tract infection
WBC: white blood cell

Introduction

Males with testicular torsion most commonly present with acute scrotal/testicular pain and swelling (the acute scrotum), which can also be the presenting symptoms for epididymitis-orchitis, torsion of the appendix testis, and scrotal trauma.¹⁻⁴

Testicular torsion is caused by the twisting of the spermatic cord along with the vasculature of the testicle and requires prompt surgical intervention to prevent testicular loss from ischemia.⁵⁻⁸ This occurs in approximately 1 in 1,500 to 1 in 4,000 males by the age of 25.^{9,10} It is important to quickly differentiate between the different testicular conditions associated with the acute scrotum to optimize the time to surgery in order to preserve testicular viability for those with testicular torsion.^{2,5,6,11} One study found that for males treated within six hours of the onset of

Accepted Article
symptoms there is a 90-100% rate of testicular salvage. For those treated within 6-12 hours of symptom onset the reported rate of testicular salvage was 20-50% and for those treated within 12-24 hours, the rate of testicular salvage was 0-10%.¹²

Certain presenting features including duration of pain less than 24 hours, age 11-21 years, nausea or vomiting, absent cremasteric reflex, abnormal testicular lie, testicular swelling, and/or hard testicle are more highly associated with testicular torsion; however, these features are not specific only for testicular torsion, and may be associated with other common diagnoses associated with the acute scrotum.¹³⁻¹⁷

In some cases, abdominal pain may be the only presenting symptom of testicular torsion; therefore, males patient presenting with lower abdominal pain should also be evaluated for possible torsion.¹⁸ High-resolution scrotal Doppler Ultrasonography (DUS) imaging is the gold standard for the evaluation of testicular complaints, with an estimated sensitivity ranging between 85-100% and specificity ranging between 75-100% for testicular torsion.^{4,7,11,19,20} Nonetheless, the use of DUS may prolong the time in testicular ischemia and delay time to surgery for those with testicular torsion.⁵ In addition to DUS, laboratory testing with urinalysis, urine culture and for sexually transmitted infections (STIs) are used in the evaluation of testicular complaints to evaluate for other causes of the acute scrotum, including epididymitis.^{1,2,21}

Importance

Clinical decision tools may be useful in the evaluation of the patient with an acute scrotum to identify those at high risk for torsion to obviate the need for routine ultrasound imaging or laboratory testing.^{16,17} In addition, these tools may also be useful to identify those at low risk for testicular torsion, who may not require emergent ultrasound imaging or subspecialty urology consultation. The Testicular Workup for Ischemia and Suspected Torsion (TWIST) score was previously developed to risk stratify for testicular torsion in males 3 months to 18 years old presenting with an acute scrotum. The TWIST score of 5 had the following test characteristics for torsion: sensitivity of 76% (95% confidence interval (CI) 62%,87%); specificity of 100% (95% CI 98%, 100%); and a positive predictive value (PPV) of 100% (95% CI 89%,100%).¹⁷ It has been previously validated by urologists¹⁷ and non-physician emergency department (ED) providers,²² but has not been evaluated exclusively in a population of pediatric emergency medicine providers. Most pediatric males with an acute scrotum will be initially evaluated by an emergency physician or pediatrician; therefore, validation of the TWIST score for generalizability of use in the ED is important. As the majority of pediatric males presenting with an acute scrotum do not have torsion, the use of clinical decision tools to aid in decision making around more judicious use of DUS imaging as well as laboratory testing for those at high risk for testicular torsion who may not require routine testing, may provide more efficient care, resulting in decreased ED length of stay and associated medical costs.

Goals of this Investigation

The objective of this study was to validate the TWIST scoring system to risk stratify for testicular torsion in a pediatric population of males presenting to the ED with an acute scrotum. A secondary objective of this study was to analyze laboratory evaluation with urinalysis, urine culture, and sexually transmitted infection (STI) testing in this same population.

METHODS

Study Design

We conducted a prospective observational study validating the TWIST scoring system in pediatric males presenting to the ED with acute scrotum. Institutional review board approval was obtained. As this was an observational study that did not impact management of the patient, the IRB waived consent from the study participants.

Study Setting and Population

This study was performed in the ED of a tertiary care children's hospital. Eligible participants were males, ages 3 months to 18 years, presenting to the ED with a chief complaint of testicular pain and/or swelling. Patients were excluded if their pain was due to a trauma, symptoms were present for greater than one week, there was a previous diagnosis of testicular torsion, a known history of testicular disease and/or surgery, or if a diagnosis of testicular torsion had already been confirmed or excluded (e.g. imaging obtained at a referring institution). Participants were enrolled from January 2013 through December 2015 between noon and midnight. Exceptions were during the months of April 2014 through June 2014 and September 2014

through October 2014, when there was no research coordinator support available to assist with subject recruitment and enrollment. Before the results of the patient's DUS were known, the ED research coordinator approached the ED treating physician, either attending physician or trainee (resident or pediatric emergency medicine fellow) of eligible participants to complete the TWIST score on a standardized electronic data collection form. ED physicians were also asked their most probable diagnosis based on history and physical exam findings. Electronic medical records of enrolled participants were reviewed to extract information on imaging results, urinalysis and urine culture results, STI testing results, and final diagnosis. Records for any follow-up visits in the ED or in the urology clinic were also reviewed to determine the final diagnosis. All the data were collected in a standardized form in REDCap (Research Electronic Data Capture), a secure, web-based application designed to support data capture for research studies. This electronic data capture tool was hosted at Boston Children's Hospital for this study.

Measurements and Key Outcome Measures

Derivation and validation of the TWIST score has been previously published.¹⁷ The TWIST score is based on the sum (ranging from 0-7) of the following historical and physical examination findings: testicular swelling (2 points), hard testicle (2 points), absent cremasteric reflex (1 point), nausea or vomiting (1 point), and high riding testicle (1 point). The risk stratifying scores for those at low risk for testicular torsion were 0-2 points, intermediate risk were 3-4 points, and high risk for testicular torsion were 5-7 points.¹⁷

The primary outcome was a diagnosis of testicular torsion, confirmed by surgical exploration as the final diagnosis. For the purposes of our analysis, participants who were ultimately diagnosed with intermittent testicular torsion were considered to have testicular torsion. Secondary outcomes were positive results of urinalysis, urine culture, and STI testing with the nucleic acid amplification test (NAAT).

Data Analysis

Frequencies were calculated for patient characteristics, results of diagnostic testing, and TWIST scores. To compare patient characteristics and the total TWIST score between males with and without testicular torsion, risk differences with 95% CI were calculated. Univariate logistic regression was performed to compare individual components of the TWIST score in those patients with and without testicular torsion to calculate the odds ratios (OR) with 95% confidence intervals (CI). The kappa statistic was also calculated among a convenience sample of 54 males to evaluate the inter-rater reliability for each of the individual components of the TWIST score and the overall score.

To evaluate test performance of the TWIST score to predict testicular torsion, test characteristics at three cut-points (scores 5, 6, and 7) were calculated to determine the sensitivity, specificity, positive predictive value (PPV), negative predictive value (NPV), positive likelihood ratio (LR), and negative LR. A receiver-operator characteristic (ROC) curve was used to calculate the area under the curve (AUC) for the 8 possible points for the TWIST score for both the final surgical diagnosis and US diagnosis of torsion. We also analyzed the test characteristics for the physician's

clinical opinion and the final surgical diagnosis of torsion. We used STATA SE®, version 13.0 (StataCorp, College Station, TX) to conduct all statistical analyses.

RESULTS

Characteristics of Study Subjects

During the study period 258 males were enrolled in the study, and 19 were diagnosed with testicular torsion (7.4%) (Figure 1). The mean age of the enrolled (9.8 ± 0.3 years) and missed eligible patients (10.2 ± 0.3 years) were similar (difference -0.35, 95% CI -1.2, 0.55). Scrotal ultrasounds were obtained in all study subjects. Sixteen patients were diagnosed with testicular torsion by ultrasound. Three patients had ultrasounds that were abnormal, but did not demonstrate definitive torsion with lack of vascular flow. The ultrasounds for these patients demonstrated either increased flow or an enlarged ipsilateral epididymis or had intermittent testicular flow. These patients ultimately had surgical management (orchidopexy) that confirmed the diagnosis of testicular torsion; therefore, there were a total of 19 males with a final diagnosis of testicular torsion. Race and ethnicity did not differ between those with testicular torsion and those with other testicular diagnoses, although those with torsion were slightly older (Table 1). There were 22 operations performed in this study cohort. Only three patients, all of whom had DUS findings consistent with torsion, underwent an orchiectomy for an unviable testicle; all three of these patients presented after a history of testicular pain for 18-72 hours. One of these patients was developmentally delayed and nonverbal.

Main Results--TWIST Score

Males with testicular torsion had higher mean TWIST scores than those with other testicular diagnoses (risk difference 2.60, 95% CI 1.84, 3.26) (Table 2). There were higher odds for the presence of all the individual TWIST score components with a diagnosis of testicular torsion. The components of history of nausea, presence of scrotal swelling, and presence of high-riding testicle demonstrated substantial agreement between providers; however, the other two components (hard testicle, absence of cremasteric reflex), demonstrated less inter-rater reliability (Table 2). For the overall TWIST score, there was only fair agreement (κ 0.39, 95% CI 0.22, 0.46) between providers.²³

Two males with TWIST scores of 0 and 1 with testicular torsion had abnormal scrotal ultrasounds that demonstrated increased size and/or blood flow to the ipsilateral epididymis, but did not definitively demonstrate testicular torsion with lack of blood flow (Table 3). Also the male with a TWIST score of 0 and testicular torsion, did have a physical examination finding of ipsilateral scrotal swelling on review of the ED medical record, which would have given the child a TWIST score of 2, had this been documented as such. The ROC curve for the final surgical diagnosis of testicular torsion had an area under the curve (AUC) of 0.82 (95% CI 0.71, 0.94) and for the US diagnosis the AUC was 0.89 (95% CI 0.81, 0.97) (Figure 2). The TWIST score of seven had a sensitivity of 21% (95% CI 6%, 45%), a specificity of 100% (95% CI 98%, 100%), and a PPV of 100% (95% CI 40%, 100%) (Table 4). This was superior to a clinical opinion of testicular torsion, which had a sensitivity of 34% (95% CI 19%, 52%), specificity of 97% (95% CI 94%, 99%), and PPV of 63% (95% CI 38%, 84%).

Diagnostic evaluation

The findings on scrotal ultrasound for males presenting with an acute scrotum were:

hydrocele (29%), epididymitis/orchitis (28%), normal testicle (23%), torsion of the appendix testis or epididymis (14%), and testicular torsion (6%) (Table 5).

Urinalyses were performed on 224/258 (87%) of males presenting with an acute scrotum. Of those with urinalyses, one child had only a urine dipstick sent with no microscopic urinalysis or culture. He was a 10 year old male with trisomy 21 and one previous UTI who was treated presumptively with oral antibiotics for a UTI. Only two boys with urinalyses had greater than 10 WBC/hpf, but neither grew bacteria in urine culture. One of these males was a 10 year old who presented with testicular pain and fever. His UA was positive for 116 WBC and nitrites. His urine culture was sent after antibiotics were given, and he was admitted to the hospital for IV antibiotics for treatment of bacterial epididymitis/orchitis. A sexually active teenage patient had a urinalysis with large leukocyte esterase on dipstick and 7 WBC/hpf. He was treated presumptively for STI with oral and intramuscular antibiotics; however, final NAAT STI testing was negative. Urine cultures were sent on 123/258 (48%) males. Only one urine culture was positive for 50,000[>] CFU/mL *Corynebacterium*, but the UA for this patient was negative for leukocyte esterase/WBC, blood/RBC, or nitrites. This uncircumcised patient was treated with oral antibiotics for presumed infectious epididymitis. STI testing with NAAT for gonorrhea and chlamydia were uncommonly sent, 21/258 (8.1%). Only one patient had a positive result, which was for chlamydia only (negative for gonorrhea), and this patient's urinalysis was also negative.

DISCUSSION

We conducted a prospective validation study among physicians in a tertiary care pediatric ED of the TWIST score for males 3 months to 18 years old presenting with an acute scrotum. Overall, the TWIST score performed well for the final surgical diagnosis of testicular torsion with an AUC of 0.82 and with an AUC of 0.88 for the ultrasound diagnosis. When considering the final surgical diagnosis of testicular torsion, the TWIST score of 7 had 100% specificity and 100% PPV for torsion, which is superior to clinical opinion. Urinalyses were frequently performed, while urine cultures and STI testing were much less commonly done, with rare positive results.

Two decision tools created to risk stratify patients presenting with an acute scrotum for testicular torsion have been recently published.^{16,17} This current study of pediatric ED physicians is a prospective validation of the TWIST score, which risk stratifies patients presenting with an acute scrotum for testicular torsion.¹⁷ On the retrospective and prospective validation cohorts of the original study, using data collected by urologists, the low (0-1 point) and high risk (6-7 points) cutoffs were found to have negative and positive predictive values of 100%. The authors of the TWIST score concluded using the low and high risk score categories could potentially decrease DUS use in up to 80% of cases.¹⁷ In this current study cohort using data collected by attending and trainee physicians in a pediatric ED, the TWIST score did not perform as well, with an AUC for ultrasound diagnosis of testicular torsion of 0.82, compared to the original study where the AUC was 0.98 for the prospective cohort and 0.996 for the retrospective cohort.¹⁷ It is possible this is due to the different specialties represented in the two studies. This may also be due to the fact that no specific training was conducted in use of the TWIST score for the

ED physicians, which is the way it would be commonly implemented in the ED setting. Broadening the DUS findings diagnostic for testicular torsion would have also better captured all the males with the final surgical diagnosis of torsion. The prospective validation set of the original TWIST study included no patients with torsion (0/51) in the low risk category (score 0-2) and 100% of patients with torsion (22/22) in the high risk category (score 5-7).¹⁷

Another prospective validation study of the TWIST score using emergency medical technicians (EMTs) specifically trained to use the TWIST score had a similarly high AUC of 0.95 (95% CI 0.91, 0.98).²² They defined slightly different risk categories as low (0 points), intermediate (1-5 points), and high (6-7) points. There were also no patients with torsion 0/44 in the low risk category, and again, 100% of patients in the high risk category had torsion (15/15). In the current study a low risk score of 0-1 predicted no torsion by ultrasound, and a high risk score of 7 predicted testicular torsion in four out of four males. For males with a score of 7, consultation with a urologist before obtaining an ultrasound could be considered to potentially expedite surgical management of testicular torsion. The two patients with the low risk score of 0 and 1 who did have testicular torsion determined during surgical exploration, did have abnormal DUS findings of the epididymis with increased flow to the epididymis,¹¹ which led to their ultimate surgical management and diagnosis of torsion. Based on this limited sample size, we would still recommend obtaining a DUS even in this low risk group for the potential of missing an intermittent torsion or torsion without the typical DUS findings of lack of testicular blood flow.

Another prospective study derived a low-risk clinical decision rule for testicular torsion using recursive partitioning. This rule consists of three variables: horizontal or inguinal testicular lie, nausea or vomiting, and age 11-21 years. The test characteristics of this rule for testicular torsion in a prospective validation set included a sensitivity 100% (95% CI 98%, 100%) and a NPV of 100% (95% CI 98%, 100%). The authors concluded that patients with normal testicular lie, lack of nausea or vomiting, and age 0-10 years old were associated with no risk of testicular torsion. The authors recommended that patients who do not meet all three criteria undergo emergent evaluation for possible torsion. This decision rule may be easier for clinicians to use as fewer factors are included; however, it has not been externally validated.¹⁶

Urinalysis in the setting of an acute scrotum is for the identification of pyuria as a potential marker for infectious epididymitis,² which may occur secondary to retrograde flow of infected urine from the urethra through the ejaculatory ducts and vas deferens into the epididymis.^{2,4} Previous studies have demonstrated most pediatric males with epididymitis do not have pyuria on urinalysis or a positive urine culture;^{24,25} and therefore, do not require routine antibiotic treatment.²⁴⁻²⁶ As there are no clear predictors for males with a bacterial etiology of epididymitis the general recommendation is for a urine culture to be performed on males with epididymitis,^{21,24,25} while the utility of a screening urinalysis for pyuria is less clear. In our study cohort urinalysis was performed in 86% of males without testicular torsion and 0% in males with torsion. Urine cultures were sent for 52% of males, and only one urine culture was considered positive for bacterial epididymitis with > 50,000 CFU/mL *Corynebacterium*. This patient's urinalysis was negative for all components. Some

authors recommend that males with epididymitis be managed conservatively with NSAIDs and scrotal elevation without empiric antibiotics, and also recommend urine cultures be sent and antibiotic therapy determined from these results.² Based on our results, it may be reasonable to consider this approach in males with no past urologic history, who are at low risk for infection.

In sexually active adult males, STIs are a common cause of epididymitis/orchitis;^{13,24} however, STI testing was uncommonly performed in this study cohort, who were evaluated in a pediatric ED. Only 21 (3.1%) of males had STI testing performed, and only one STI test was positive. Testing for *C. trachomatis* and *N. gonorrhoea* by culture or NAAT with appropriate antibiotic treatment is the recommendation for sexually active males presenting with an acute scrotum.^{1,24} A more standardized approach for STI testing in adolescent males with an acute scrotum may be useful to improve diagnosis and treatment this population.

LIMITATIONS

Our study must be considered in the context of several limitations. This was a convenience sample of patients, and only 52% of eligible patients were enrolled.

Lack of continuous research coordinator coverage during the study period primarily due to staffing challenges as well as hours of coverage was the cause of these missed eligible patients, who also had a higher percentage of testicular torsion.

Lower numbers than expected of testicular torsion, based on previous studies of males with torsion, were included in this study, although the reasons for this are unclear. As a result of the lower sample size for the primary outcome of testicular torsion, there was less precision in the point estimates for the test characteristics of

the various cut points for the TWIST score. Specific training around use of the TWIST scoring system was not performed for the physicians, which may have biased the test characteristics of the TWIST score for risk stratification, especially in the low risk group. Also, although we reviewed the records of all the study patients for any ED or urology visits within 30 days of the index ED visit for cases of testicular torsion not identified on the first visit, it is possible that the patient had follow up at another institution that wouldn't be captured in our dataset. This prospective validation study used data collected by attending and trainee physicians in a pediatric ED at a tertiary care pediatric hospital, which may limit the generalizability of the results to providers who are less specialized in caring for children and adolescents.

CONCLUSIONS

In conclusion, the TWIST score of 7 accurately identified males presenting with testicular torsion. Although the low risk TWIST score of 0-1 was associated with no males with testicular torsion on the initial ED DUS, two patients were subsequently diagnosed with torsion with other abnormal ED DUS findings; therefore, use of DUS would still be recommended for males with this low score. Based on these results, the TWIST score may be used as part of the decision making in the evaluation the acute scrotum, particularly for those with a score of 7 where emergent urology or surgical consultation would be recommended. Urinalysis was not useful in assisting with the decision-making regarding antibiotic use for possible bacterial epididymitis. Future studies may consider evaluating the utility of performing urine culture and comparing to urinalysis results to determine best recommendations for testing for males with epididymitis/orchitis. STI testing was infrequently performed, but should be considered in sexually active males presenting with an acute scrotum.

Development of evidence based clinical guidelines for the evaluation of the pediatric acute scrotum may be useful to provide more timely care in the diagnosis and surgical management of testicular torsion. These guidelines may also decrease unnecessary urinalysis testing for males without epididymitis/orchitis while improving diagnosis and treatment of males with STI. The evaluation of this type of guideline for the evaluation of the acute scrotum may result in more standardized and effective care.

Acknowledgements

We thank the research coordinators in the emergency department for recruiting the physicians who contributed data to the study. We also thank Dr. Michael Monuteaux for his guidance on the statistical analysis for this study.

REFERENCES

1. Jefferies MT, Cox AC, Gupta A, Proctor A. The management of acute testicular pain in children and adolescents. *BMJ* [Internet] 2015 [cited 2016 Jan 25];350(apr02_5):h1563. Available from: <http://www.bmj.com.ezproxy.bu.edu/content/350/bmj.h1563.full.pdf+html>
2. Diaz EC, Kimball D, Gong EM. Acute Scrotal Pain in Pediatric Emergency Medicine: Assessment, Diagnosis, Management, and Treatment. *Clin Pediatr Emerg Med* [Internet] 2014 [cited 2016 Feb 1];15(3):248–60. Available from: <http://www.sciencedirect.com/science/article/pii/S1522840114000652>
3. Boettcher M, Bergholz R, Krebs TF, Wenke K, Aronson DC. Clinical predictors of testicular torsion in children. *Urology* 2012;79(3):670–4.

- Accepted Article
4. Vasdev N, Chadwick D, Thomas D. The acute pediatric scrotum: Presentation, differential diagnosis and management. *Curr. Urol.* 2012;6(2):57–61.
 5. Lewis AG, Bukowski TP, Jarvis PD, Wacksman J, Sheldon CA. Evaluation of acute scrotum in the emergency department. *J Pediatr Surg* [Internet] 1995;30(2):277-81-2. Available from:
<http://www.ncbi.nlm.nih.gov/pubmed/7738751>
 6. Ramachandra P, Palazzi KL, Holmes NM, Marietti S. Factors influencing rate of testicular salvage in acute testicular torsion at a tertiary pediatric center. *West J Emerg Med* [Internet] 2015;16(1):190–4. Available from:
<http://www.pubmedcentral.nih.gov/articlerender.fcgi?artid=4307716&tool=pmc-entrez&rendertype=abstract>
 7. Sharp VJ, Kieran K, Arlen AM. Testicular torsion: diagnosis, evaluation, and management. *Am Fam Physician* [Internet] 2013;88(12):835–40. Available from: <http://www.ncbi.nlm.nih.gov/pubmed/24364548>
 8. Vasdev N, Chadwick D, Thomas D. The acute pediatric scrotum: Presentation, differential diagnosis and management [Internet]. *Curr. Urol.* 2012;6(2):57–61. Available from:
<http://ovidsp.ovid.com/ovidweb.cgi?T=JS&PAGE=reference&D=emed10&NEWS=N&AN=2012591943>
 9. Zhao LC, Lautz TB, Meeks JJ, Maizels M. Pediatric Testicular Torsion Epidemiology Using a National Database: Incidence, Risk of Orchiectomy and Possible Measures Toward Improving the Quality of Care. *J Urol* [Internet] 2011;186(5):2009–13. Available from:

<http://dx.doi.org/10.1016/j.juro.2011.07.024>

10. Williamson RC. Torsion of the testis and allied conditions. *Br J Surg* [Internet] 1976;63(6):465–76. Available from: <http://www.ncbi.nlm.nih.gov/pubmed/6106>
11. Liang T, Metcalfe P, Sevcik W, Noga M. Retrospective review of diagnosis and treatment in children presenting to the pediatric department with acute scrotum. *Am J Roentgenol* [Internet] 2013;200(5):W444-9. Available from: <http://eutils.ncbi.nlm.nih.gov/entrez/eutils/elink.fcgi?dbfrom=pubmed&id=23617512&retmode=ref&cmd=prlinks%5Cnpapers3://publication/doi/10.2214/AJR.12.10036>
12. Pogorelic Z, Mustapic K, Jukic M, et al. Management of acute scrotum in children: a 25-year single center experience on 558 pediatric patients. *Can J Urol* 2016;23(6):8594–601.
13. Kadish HA, Bolte RG. A retrospective review of pediatric patients with epididymitis, testicular torsion, and torsion of testicular appendages. *Pediatrics* 1998;102(1 Pt 1):73–6.
14. Beni-Israel T, Goldman M, Bar Chaim S, Kozer E. Clinical predictors for testicular torsion as seen in the pediatric ED. *Am J Emerg Med* [Internet] 2010;28(7):786–9. Available from: <http://dx.doi.org/10.1016/j.ajem.2009.03.025>
15. Srinivasan A, Cinman N, Feber KM, Gitlin J, Palmer LS. History and physical examination findings predictive of testicular torsion: an attempt to promote clinical diagnosis by house staff. *J Pediatr Urol* [Internet] 2011 [cited 2016 Feb 1];7(4):470–4. Available from: <http://www.ncbi.nlm.nih.gov/pubmed/21454130>
16. Shah MI, Chantal Caviness A, Mendez DR. Prospective pilot derivation of a

decision tool for children at low risk for testicular torsion. Acad Emerg Med [Internet] 2013;20(3):271–8. Available from:

<http://www.ncbi.nlm.nih.gov/pubmed/23517259>

17. Barbosa JA, Tiseo BC, Barayan GA, et al. Development and initial validation of a scoring system to diagnose testicular torsion in children. J Urol [Internet] 2013;189(5):1859–64. Available from:
<http://dx.doi.org/10.1016/j.juro.2012.10.056>
18. Pogorlic Z, Mrklic I, Juric I. Do not forget to include testicular torsion in differential diagnosis of lower acute abdominal pain in young males. J Pediatr Urol 2013;9:1161–5.
19. Yagil Y, Naroditsky I, Milhem J, et al. Role of Doppler ultrasonography in the triage of acute scrotum in the emergency department. J Ultrasound Med 2010;29:11–21.
20. Cokkinos DD, Antypa E, Tserotas P, et al. Emergency ultrasound of the scrotum: a review of the commonest pathologic conditions. Curr Probl Diagn Radiol [Internet] 2011;40(1):1–14. Available from:
<http://www.ncbi.nlm.nih.gov/pubmed/21081208>
21. Gkentzis A, Lee L. The aetiology and current management of prepubertal epididymitis. Ann R Coll Surg Engl [Internet] 2014 [cited 2016 Feb 1];96(3):181–3. Available from: <http://www.ncbi.nlm.nih.gov/pubmed/24780779>
22. Sheth KR, Keays M, Grimsby GM, et al. Diagnosing Testicular Torsion before Urological Consultation and Imaging: Validation of the TWIST Score. J Urol [Internet] 2016 [cited 2016 Mar 24]; Available from:

<http://www.sciencedirect.com/science/article/pii/S002253471600224X>

23. Landis JR, Koch GG. The measurement of observer agreement for categorical data. *Biometrics* 1977;33(1):159–74.
24. Santillanes G, Gausche-Hill M, Lewis RJ. Are antibiotics necessary for pediatric epididymitis? *Pediatr Emerg Care* [Internet] 2011 [cited 2016 Feb 1];27(3):174–8. Available from: <http://www.ncbi.nlm.nih.gov/pubmed/21346680>
25. Joo JM, Yang SH, Kang TW, Jung JH, Kim SJ, Kim KJ. Acute epididymitis in children: The role of the urine test. *Korean J Urol* 2013;54(2):135–8.
26. Somekh E, Gorenstein A, Serour F. Acute epididymitis in boys: evidence of a post-infectious etiology. *J Urol* [Internet] 2004 [cited 2016 Feb 1];171(1):391–4; discussion 394. Available from: <http://www.ncbi.nlm.nih.gov/pubmed/14665940>

Table 1. Characteristics of Study Subjects

Characteristic	Surgical Diagnosis of Testicular Torsion (N=19)	No Torsion (N= 239)	Difference* (95% CI)
Age, mean (SD)**	12.53 (4.26)	9.64 (5.04)	2.89 (0.54, 5.23)
Race, n (%)			
White	10 (52.6%)	152 (63.6%)	-0.11 (-0.34, 0.12)
Black	4 (21.0%)	17 (7.1%)	0.14 (-0.05, 0.32)
Asian	1 (5.3%)	12 (5.0%)	0.002 (-0.10, 0.11)
Other/Unknown	4 (21.0%)	58 (24.3%)	-0.32 (-0.22, 0.16)
Ethnicity, n (%)			
Hispanic	1 (5.3%)	23 (9.6%)	-0.04 (-0.15, 0.06)
Non-Hispanic	15 (78.9%)	165 (69.0%)	0.10 (-0.09, 0.29)
Unknown	3 (15.8%)	51 (21.3%)	-0.05 (-0.23, 0.12)
Duration of scrotal pain/swelling, n (%)			
Unknown***	4 (21.0%)	115 (48.1%)	---
< 6 hours	7 (3.8%)	32 (13.4%)	0.08 (-0.08, 0.25)
7-12 hours	3 (15.8%)	29 (12.1%)	0.02 (-0.08, 0.13)
13-24 hours	3 (15.8%)	18 (7.5%)	-0.04 (-0.07, -0.16)
25-36 hours	0 (0%)	10 (4.2%)	0.01 (-0.09, 0.11)
37-48 hours	1 (5.3%)	10 (4.2%)	0.04 (-0.13, 0.21)
49-72 hours	1 (5.3%)	7 (2.9%)	0.23 (0.01, 0.45)
> 72 hours	0 (0%)	17 (7.1%)	-0.07 (-0.10, -0.04)
Clinical Opinion of Treating MD, n (%)			
Testicular torsion	12 (63.2%)	23 (9.6%)	0.53 (0.31, 0.75)
Epididymitis/Orchitis	5 (26.3%)	114 (47.7%)	-0.28 (-0.47, -0.08)
Torsion of appendix testis/epididymis	0 (0%)	32 (13.4%)	-0.09 (-0.20, 0.02)
Hernia	0 (0%)	12 (5.0%)	-0.05 (-0.08, -0.02)
Other	2 (10.5%) <i>int. tors.</i>	58 (24.0%)	-0.15 (-0.30, -0.005)

*Risk difference with 95% confidence intervals, except for age.

** For age (continuous variable) mean difference was calculated.

*** Duration of pain not recorded for entire length of study.

Table 2. TWIST Score Components

TWIST Score Components	Testicular Torsion	No Torsion	OR (95% CI)	Kappa Statistic (95% CI)
History of nausea, n (%)	11 (57.9%)	28 (11.7%)	10.36 (3.84, 27.95)	0.75 (0.53, 0.98)
Scrotal swelling, n (%)	15 (78.9%)	111 (46.4%)	4.32 (1.39, 13.41)	0.74 (0.56, 0.92)
High-riding testicle, n (%)	11 (57.9%)	55 (23.0%)	4.60 (1.76, 12.00)	0.63 (0.40, 0.86)
Absent cremasteric reflex, n (%)	12 (63.2%)	62 (25.9%)	4.89 (1.84, 12.99)	0.52 (0.27, 0.77)
Hard testicular mass, n (%)	8 (42.1%)	15 (6.3%)	10.86 (3.80, 31.04)	0.25 (-0.20, 0.69)
Total TWIST Score, mean (range)	4.21 (0-7)	1.66 (0-6)	2.60 (1.84, 3.26)*	0.39 (0.22, 0.46)

*Mean difference for total TWIST score.

Table 3. TWIST Score by Diagnosis of Testicular Torsion

TWIST Score	Final Surgical Diagnosis of Testicular Torsion		Ultrasound Diagnosis of Testicular Torsion	
	Testicular Torsion (19) n(%)	No Torsion n/N (%) (239)	Testicular Torsion (16) N (%)	No Torsion (242) N (%)
0	1 *(5.26%)	72 (30.13%)	0 (0%)	73 (30%)
1	1 *(5.26%)	37 (15.48%)	0 (0%)	38 (16%)
2	3 (15.79%)	67 (28.03%)	3 (19%)	67 (28%)
3	2 (10.53%)	36 (15.06%)	2 (12%)	36 (15%)
4	3 (15.79%)	20 (8.37%)	2 (12%)	21 (8.7%)
5	3 (15.79%)	4 (1.67%)	3 (19%)	4 (1.6%)
6	2 (10.53%)	3 (1.26%)	2 (12%)	3 (1.2%)
7	4 (21.05%)	0 (0%)	4 (25%)	0 (0%)

*US with testicular flow with increased prominence of epididymis and blood flow to epididymis.

Table 4. Test Performance of TWIST Score to Predict Testicular Torsion* (n=258)

TWIST Cut-Point	Sensitivity (95% CI)	Specificity (95% CI)	PPV (95% CI)	NPV (95% CI)	Positive LR	Negative LR
5	47 (24, 71)	97 (94, 99)	56 (30,80)	96 (92, 98)	16.17	0.54
6	32 (13,56)	99 (96, 99)	67 (30, 92)	95 (91, 97)	25.06	0.69
7	21 (6, 45)	100 (98, 100)	100 (40, 100)	94 (90, 97)	0.00	0.79

*Based on final surgical diagnosis.

Table 5. Diagnostic Evaluation

Diagnostic Evaluation	Testicular Torsion n/N (%)	No Testicular Torsion n/N (%)
Urinalysis	6/19 (31.6%)	205/239 (85.8%)
Leukocyte esterase positive	0/6 (0%)	6/205 (2.9%)
> 10 WBC/hpf	0/6 (0%)	2/205 (1.0%)
Blood positive	0/6 (0%)	13/205 (6.4%)
> 10 RBC/hpf	0/6 (0%)	0/205 (0%)
Nitrite positive	0/6 (0%)	3/205 (1.5%)*
Urine culture > 50,000 CFU/mL	0/6 (0%)	1/117 (0.8%)
Urine GC/Chlamydia NAAT test	0/19 (0%)	21/239 (8.8%)
Gonorrhea positive	0/0 (0%)	0/21 (0%)
Chlamydia positive	0/0 (0%)	1/21 (4.8%)
Scrotal ultrasound results	19/19 (100%)	239/239 (100%)
Normal testicle	0/19 (0%)	59/239 (24.7%)
Testicular torsion	16/19 (84.2%)	0/239 (0%)
Epididymitis/Orchitis	0/19 (0%)	3/239 (30.5%)
Torsion of appendix testis/epididymis	0/19 (0%)	36/239 (15.1%)
Hernia	0/19 (0%)	4/239 (1.7%)
Hydrocele	8/19 (42.1%)	75/239 (31.4%)
Varicocele	1/19 (5.3%)	25/239 (10.5%)
Other**	2/19 (10.5%)	51/239 (21.3%)
Urology consult	19 (100%)	187/239 (78.24%)

*Two samples were negative on repeat UA. Urine cultures for all three patients were negative for bacterial growth.

**Increased prominence of epididymis with increased blood flow.

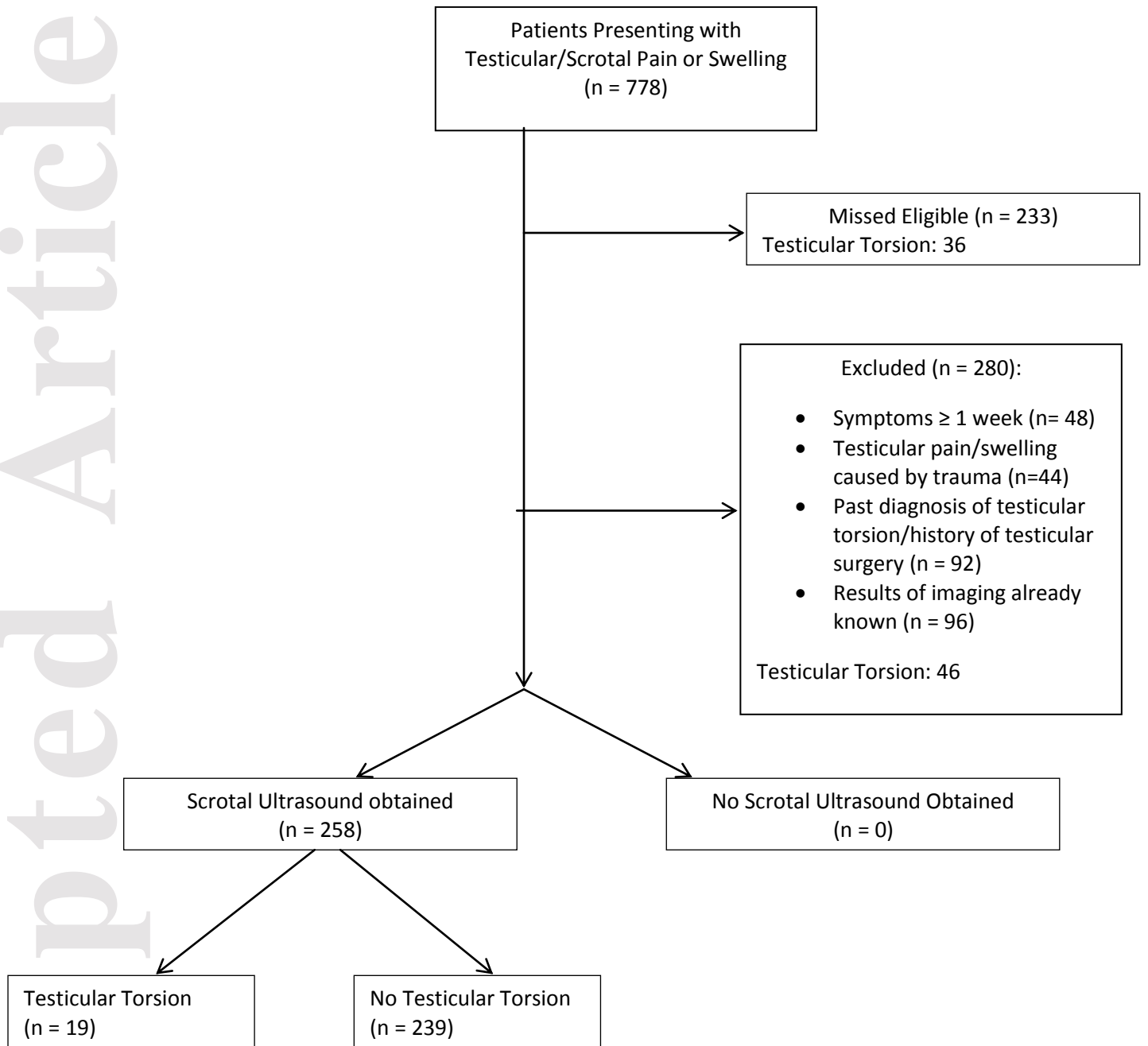
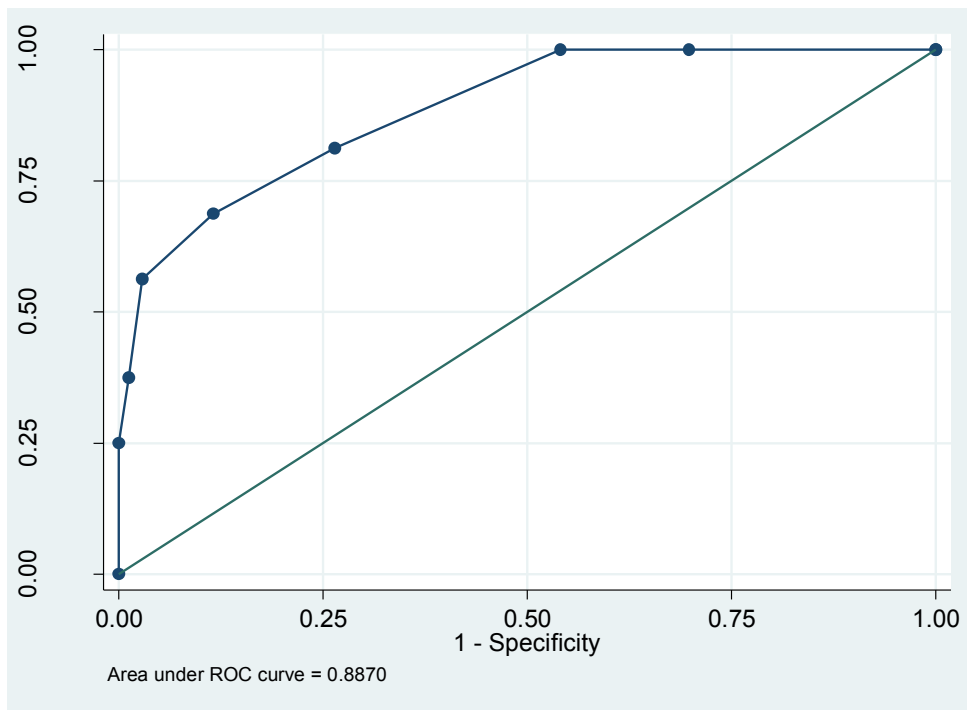


Figure 2. ROC Curves for TWIST Score

ROC Curve for TWIST Score and US Diagnosis of Testicular Torsion



ROC Curve for TWIST Score and Final Surgical Diagnosis of Testicular Torsion

