

## Clinical Article

# Clinical Features of Wrist Drop Caused by Compressive Radial Neuropathy and Its Anatomical Considerations

Bo Ram Han, M.D., Yong Jun Cho, M.D., Ph.D., Jin Seo Yang, M.D., Suk Hyung Kang, M.D., Ph.D., Hyuk Jai Choi, M.D., Ph.D.

Department of Neurosurgery, Chuncheon Sacred Heart Hospital, College of Medicine, Hallym University, Chuncheon, Korea

**Objective :** Posture-induced radial neuropathy, known as *Saturday night palsy*, occurs because of compression of the radial nerve. The clinical symptoms of radial neuropathy are similar to stroke or a herniated cervical disk, which makes it difficult to diagnose and sometimes leads to inappropriate evaluations. The purpose of our study was to establish the clinical characteristics and diagnostic assessment of compressive radial neuropathy.

**Methods :** Retrospectively, we reviewed neurophysiologic studies on 25 patients diagnosed with radial nerve palsy, who experienced wrist drop after maintaining a certain posture for an extended period. The neurologic presentations, clinical prognosis, and electrophysiology of the patients were obtained from medical records.

**Results :** Subjects were 19 males and 6 females. The median age at diagnosis was 46 years. The right arm was affected in 13 patients and the left arm in 12 patients. The condition was induced by sleeping with the arms hanging over the armrest of a chair because of drunkenness, sleeping while bending the arm under the pillow, during drinking, and unknown. The most common clinical presentation was a wrist drop and paresthesia on the dorsum of the 1st to 3rd fingers. Improvement began after a mean of 2.4 weeks. Electrophysiologic evaluation was performed after 2 weeks that revealed delayed nerve conduction velocity in all patients.

**Conclusion :** Wrist drop is an entrapment syndrome that has a good prognosis within several weeks. Awareness of its clinical characteristics and diagnostic assessment methods may help clinicians make diagnosis of radial neuropathy and exclude irrelevant evaluations.

**Key Words :** Radial nerve · Entrapment syndrome · Posterior interosseous nerve · Superficial radial nerve · Arcade of Frohse.

## INTRODUCTION

Wrist drop is caused by damage to the radial nerve, which travels down the arm and controls the movement of the triceps muscle at the back of the upper arm, because of several conditions. This nerve controls the backward bend of wrists and helps with the movement and sensation of the wrist and fingers. Posture-induced radial neuropathy is produced by entrapment of the radial nerve, which spirals around the humerus. '*Saturday night palsy*' or '*Sleep paralysis*' receives its name from episodes of unintentional prolonged radial nerve compression, because of sleeping after alcohol or drug intoxication. Its clinical symptoms include motor weakness with sensory disturbances and are similar to stroke or a herniated cervical disk and other neuropathies, which makes it difficult to diagnose appropriately and, thus, sometimes leads to inappropriate evaluations. The purpose of this study was to evaluate the clinical

characteristics and neurophysiologic features of compressive radial neuropathy and review its anatomical features related to wrist drop.

## MATERIALS AND METHODS

From January 2011 to June 2013, a retrospective study was performed on 25 patients diagnosed with radial nerve palsy in neurophysiologic analyses among patients who had experienced wrist drop after maintaining a certain posture for an extended period. All patients complained of abrupt wrist drop with or without sensory disturbances. Patients' demographic data and information on individual clinical features such as motor and sensory presentations, related postures, individual neural compression times, and clinical improvement, were retrieved from medical records with a follow-up period of 2 to 8 weeks. The results of neurophysiologic examinations were also

• Received : September 2, 2013 • Revised : December 24, 2013 • Accepted : February 13, 2014

• Address for reprints : Yong Jun Cho, M.D., Ph.D.

Department of Neurosurgery, Chuncheon Sacred Heart Hospital, College of Medicine, Hallym University, 77 Sakju-ro, Chuncheon 200-704, Korea  
Tel : +82-33-240-5171, Fax : +82-33-242-9970, E-mail : nssur771@hallym.or.kr

• This is an Open Access article distributed under the terms of the Creative Commons Attribution Non-Commercial License (<http://creativecommons.org/licenses/by-nc/3.0>) which permits unrestricted non-commercial use, distribution, and reproduction in any medium, provided the original work is properly cited.

reviewed. Nerve conduction velocity (NCV) was compared with that of the non-affected side, and affected muscles, confirmed by electromyography (EMG), were identified. For statistical analysis, the differences in nerve conduction velocity between affected and non-affected sides were assessed using the Mann-Whitney test. Null hypotheses of no difference were rejected if  $p$ -values were less than 0.05 as analyzed using the SPSS 12.0 statistical software.

## RESULTS

Subjects were 19 (76%) males and 6 (24%) females. The median age at diagnosis was 46 years (range, 20–79 years). The right arm was affected in 13 patients and left arm in 12 patients.

### Clinical features of patients with radial neuropathy (Fig. 1)

The condition was induced by sleeping with the arms hanging over the armrest of a chair because of drunkenness (17 patients), sleeping while bending the arm under the pillow (5 patients), during drinking (1 patient), and unknown (2 patients). The mean prolonged neural injury time was 178.8 minutes.

The most common clinical presentation was wrist drop and paresthesia on the dorsum of the 1st to 3rd fingers assessed through physical examination; 5 patients complained of finger drop without sensory disturbances. Subjective clinical improvement began with sensory recovery after an average of 2.4 weeks (within 2 weeks, 17 patients; from 2 to 4 weeks, 7 patients; after 5 weeks, 1 patient) and was not related to neural compression times.

### Neurophysiologic study

Electrophysiologic evaluation was performed after 2 weeks, which revealed delayed nerve conduction velocity as compared with that in the non-affected side in all patients. The mean sen-

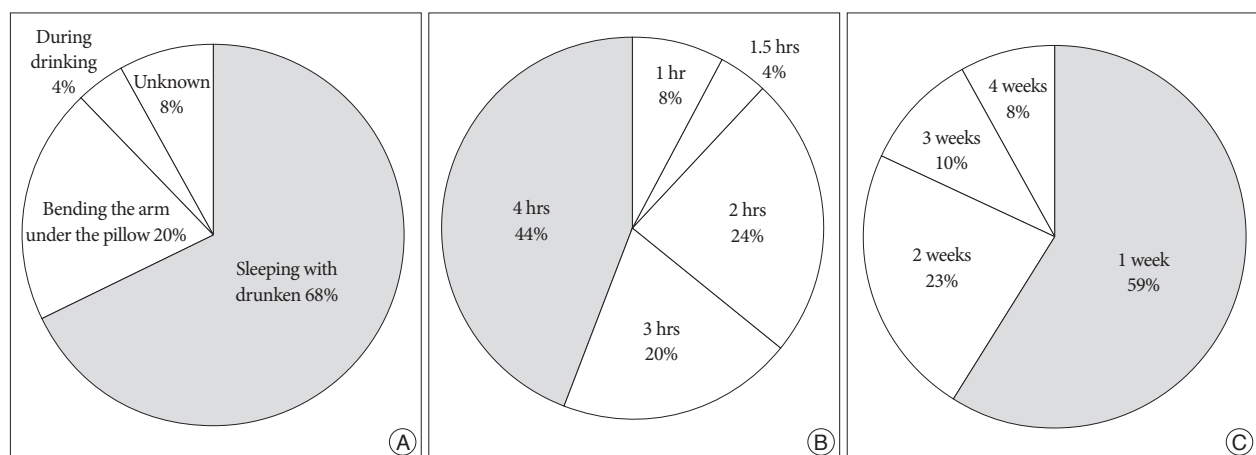
sory NCV of the affected arm was lower (42.9 m/s) than that (47.0 m/s) of the non-affected arm ( $p=0.017$ ). However, there was no significant difference in motor NCV between the affected arm (56.7 m/s) and the non-affected arm (60.8 m/s,  $p=0.002$ ). Acute fibrillation and positive sharp waves were detected in the brachioradialis (22 patients), extensor digitorum communis (18 patients), supinator (16 patients), extensor indicis proprius (15 patients), extensor carpi radialis longus (14 patients), and extensor carpi ulnaris (12 patients) on EMG.

## DISCUSSION

The radial nerve is composed of branches of the C5 through T1 nerve roots and arises from the posterior cord of the brachial plexus within the axilla. It runs over the dorsal surface of the humerus in the spiral groove supplying the extensor muscles of the upper arm. The motor component of the radial nerve innervates the triceps, anconeus, brachialis, brachioradialis, supinator, abductor pollicis longus, and the forearm extensor muscle, thereby enabling elbow extension, wrist extension, part of elbow flexion, forearm supination, and thumb extension and abduction<sup>8</sup>. The sensory component of the radial nerve carries cutaneous afferent branches from the posterior arm, forearm, and hand.

At the elbow level, the arcade of Frohse, the radial nerve bifurcates into the posterior interosseous nerve (PIN) and the superficial radial nerve (SRN). The PIN supplies the forearm extensor muscles without sensory branches and does not enter into the hand. The SRN runs into the hand and innervates the cutaneous dorsal part of the hand. Because each nerve has a different potential, this bifurcated course is important for localizing the origins of pathological lesions during diagnostic examinations (Fig. 2).

There are 3 types of radial neuropathy, according to the level of injury : PIN palsy, SRN palsy, and combined<sup>6,8-10</sup>. The PIN is



**Fig. 1.** Clinical characteristics of patients with compressive radial neuropathy and its prognosis. A : Radial neuropathy was caused by sleeping after getting drunk in 68% of patients, and in another 20% of patients it was associated with sleep posture such as bending the arm under the pillow. Overall, 88% of cases were related to sleep postures. B : Most (88%) of the patients were exposed to compression for 2–4 h, and the average time to develop neuropathy was 178.8 minutes. C : Subjective clinical improvements (decreased paresthesia, recovery of wrist or finger extensor) began after a mean of 2.4 weeks. Most (82%) of the patients felt sensory improvement within 2 weeks.

most vulnerable to entrapment just beyond its origin as it passes beneath the arcade of Frohse at the proximal edge of the supinator in the radial tunnel<sup>9</sup>. Compression of the PIN alone may manifest as pure motor weakness in its distribution, resulting in the inability to extend the metacarpophalangeal joints of the finger and thumb, as well as weakness in extending the thumb at the interphalangeal joint, which is also called “finger drop.” Usually, there is no complete wrist drop because the extensor carpi radialis longus is supplied by the radial nerve proximal to its terminal branch. Compression of the superficial sensory branch alone may present as paresthesia and decreased sensation along the cutaneous area on the radial side of the dorsum of the hand<sup>5,6</sup>.

A radial nerve injury above the elbow, such as the “Saturday night palsy” or “Sleep paralysis,” may present with extensor weakness of the elbow, wrist, and finger, accompanied by sensory disturbance along the PIN and SRN<sup>2,4,11</sup>. In this study, 20 patients experienced wrist drop and finger drop with decreased posterolateral hand sensation, and 5 patients presented with weak thumb and finger extensors and preserved wrist extension. Awareness of the usual entrapment site of the radial nerve with its motor function is crucial for localizing the lesion. A high radial neuropathy proximal to the spiral groove results in the weakness in elbow extension, wrist extension, and thumb and finger extension. A radial neuropathy above the elbow presents with preserved strength in elbow extension and weakness in wrist, thumb, and finger extension, and to some degree, elbow flexion, forearm supination, and thumb abduction. A radial neuropathy distal to the spiral groove and proximal to the division of the PIN shows preserved elbow extension, weak thumb and finger extensors, and varying degrees of wrist extension and elbow flexion weakness depending on the exact location of the lesion. A PIN lesion indicates preserved strength in elbow extension, wrist extension with radial deviation, and elbow flexion. We assumed that 20 of the patients had injuries in the spi-

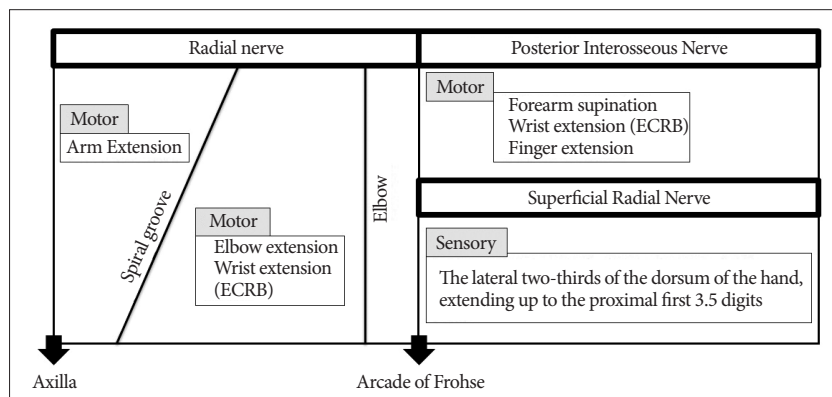
ral groove, and 5 patients had injuries proximal to the arcade of Frohse.

Sensory examination of the radial nerve should include pinprick and light touch testing of the posterior arm and forearm and of the posterior lateral hand and thumb. Sensory loss over all of these areas implicates a radial nerve lesion above the spiral groove. Sensory loss over the posterior lateral hand and thumb, with intact sensation over the posterior arm and forearm, is consistent with an SRN lesion or a radial nerve lesion at the spiral groove.

Neurophysiologic evaluations may confirm the diagnosis and establish the site of injury. In most cases of compressive radial neuropathy, the type of injury is a “neuropraxia” that does not involve damage to the axon. Neuropraxia is classified as a transient conduction block of motor or sensory function without neuronal degeneration. Therefore, despite decreased motor function, patients with neuropraxia are able to regain normal neurologic function within several weeks to months. In this study, 82% of all patients felt a beginning of improvement of sensory deficit within 2 weeks. Eighteen percent of all patients had improved after 2 weeks, and there were no correlations between neural compression time and the beginning of clinical improvement. The peripheral nerve is embedded in epineural tissues, which are different in each individual. Therefore, identical neural injury times do not always lead to the same neural injury, and depending on the individual conditions, different injuries may be induced.

Normal sensory nerve action potential (SNAP) values include an amplitude of  $\geq 15 \mu V$ , a peak distal latency of  $\leq 2.8$  ms, and a velocity of  $\geq 50$  m/s<sup>9</sup>. The SNAP may be abnormal in cases of SRN and normal in PIN neuropathy with unaffected SRN or a herniated cervical disk and other diseases. The motor nerve conduction study is easily performed by stimulating the radial nerve in the mid to upper forearm, at the elbow between the brachioradialis and the biceps tendon, and at the arm above and below the spiral groove. Normal compound muscle action

potential (CMAP) values include an amplitude of  $\geq 2$  mV, a distal motor latency of  $\leq 3.3$  ms, and a conduction velocity of  $\geq 49$  m/s. However, because of volume-conducted potentials from the radial forearm muscles and the tortuous course of the radial nerve in the forearm, the CMAP may have an initial positive deflection leading to difficulty in accurate measurement. For this reason, measurement of motor NCS is useful in the spiral groove lesions<sup>11</sup>. EMG may reveal abnormalities in radial-innervated muscles (brachioradialis, extensor digitorum communis, supinator, extensor indicis proprius, extensor carpi radialis longus, and extensor carpi ulnaris). Acute fibrillation potentials or



**Fig. 2.** Schematic illustration of the distribution and functions of the radial nerve and its branches. At the level of the “arcade of Frohse,” the radial nerve bifurcates into the posterior interosseous nerve (PIN) and the superficial radial nerve (SRN). A radial nerve injury above the elbow may present with weakness of elbow extension and wrist extension with decreased sensation in the distributions of both the PIN and SRN. This bifurcated location is important in localizing the origins of the pathologic lesion during diagnostic examinations.

positive sharp waves imply an acute lesion and is useful in localization<sup>7</sup>.

There are other neurologic disorders that are similar to radial neuropathy, and there are some clues that can be used to distinguish among the affected sites, which include (from distal to proximal) the radial nerve, posterior cord, brachial plexus, cervical root, and cerebral cortex. Posterior cord plexopathy typically involves deltoid weakness and sensory loss in the shoulder as well as abnormal axillary or thoracodorsal nerve function. C7 radiculopathy or middle trunk plexopathy is less likely in the presence of preserved triceps function. In case of herniated cervical disk, signs of nerve root irritation should be evaluated for differential diagnosis. Nerve root irritation can often present as not only an unremitting dull ache in the neck, but often a sharp or burning sensation with referral arm according to neck movements.

A PIN lesion is excluded by sensory loss in the hand and wrist drop. Cerebral stroke may cause an isolated wrist drop, but it is usually accompanied by signs of other neurological symptoms, including changes in mental state, pupil size, light pupillary reflex, and unstable vital signs, etc. In addition, proximal radial neuropathy is relatively easy to differentiate by sensory impairment, wrist drop, or elbow extensor weakness because of myopathy. Lateral epicondylitis (radial tunnel syndrome or tennis elbow) may present with lateral elbow pain without sensory impairment.

Arnold et al.<sup>11</sup> reported that the outcome of nontraumatic compressive radial neuropathy is better than the outcome after trauma. Therefore, in most cases, primary treatment should involve conservative management, including observation, non-steroidal anti-inflammatory medications, avoidance of provocative activities, and the use of wrist splints. However, if symptoms persist after 3 to 6 months despite proper managements, neurolysis may be considered.

Although, the prognosis of compressive radial neuropathy has been reported to be good, denervation findings on needle EMG and severe initial weakness are reliable indicators for a poor prognosis, and such patients should be monitored closely if the weakness does not improve<sup>3</sup>.

## CONCLUSION

Compressive radial neuropathy has a good prognosis within

several weeks, even though initial symptoms are serious. Clinically, other neurological disorders may present with similar presentations of wrist or finger drop. Awareness of clinical features of this disorder and functions of the radial nerve may help clinicians differentiate between radial neuropathy and other possible diseases.

## • Acknowledgements

This study was supported by Hallym University Research Fund 2012 (HURF-2012-38) and BioGreen 21 Program (PJ009051) of Rural Development Administration.

## References

1. Arnold WD, Krishna VR, Freimer M, Kissel JT, Elsheikh B : Prognosis of acute compressive radial neuropathy. *Muscle Nerve* 45 : 893-895, 2012
2. Barton NJ : Radial nerve lesions. *Hand* 5 : 200-208, 1973
3. Bsteh G, Wanschitz JV, Gruber H, Seppi K, Löscher WN : Prognosis and prognostic factors in non-traumatic acute-onset compressive mononeuropathies - radial and peroneal mononeuropathies. *Eur J Neurol* 20 : 981-985, 2013
4. Düz B, Solmaz I, Civelek E, Onal MB, Pusat S, Daneyemez M : Analysis of proximal radial nerve injury in the arm. *Neurol India* 58 : 230-234, 2010
5. Hermansdorfer JD, Greider JL, Dell PC : A case report of a compressive neuropathy of the radial sensory nerve caused by a ganglion cyst at the elbow. *Orthopedics* 9 : 1005-1006, 1986
6. Jou IM, Wang HN, Wang PH, Yong IS, Su WR : Compression of the radial nerve at the elbow by a ganglion : two case reports. *J Med Case Rep* 3 : 7258, 2009
7. Khodulev VI, Nechipurenko NI, Antonov IP, Arkind GD : [The electro-neuromyographic study of the radial nerve : compressive ischemic neuropathy of the posterior interosseous nerve]. *Zh Nevrol Psikhiatr Im S Korsakova* 108 : 48-55, 2008
8. Kimbrough DA, Mehta K, Wissman RD : Case of the season : Saturday Night Palsy. *Semin Roentgenol* 48 : 108-110, 2013
9. Kirici Y, Irmak MK : Investigation of two possible compression sites of the deep branch of the radial nerve and nerve supply of the extensor carpi radialis brevis muscle. *Neurol Med Chir (Tokyo)* 44 : 14-18; discussion 19, 2004
10. Loh YC, Lam WL, Stanley JK, Soames RW : A new clinical test for radial tunnel syndrome--the Rule-of-Nine test : a cadaveric study. *J Orthop Surg (Hong Kong)* 12 : 83-86, 2004
11. Posner MA : Compressive neuropathies of the median and radial nerves at the elbow. *Clin Sports Med* 9 : 343-363, 1990